

---

## CASE REPORT

# Can Mycetoma Mimic Carcinoma of Lung? An Unusual Presentation of Aspergilloma: A Case Report

Niaz Hussain Soomro, Saima Imam, Aneeqa Zafar, Almas Shaheen

## ABSTRACT

This case report is of a 40 years old male who came with symptoms and radiological signs of lung cancer (i.e. hyper dense soft tissue mass of lung without Monad's sign an increase in size of the mass from 4 cm to 5.8cm compared on the 1<sup>st</sup> and 2<sup>nd</sup> CT scan and associated multiple enlarged mediastinal lymph nodes but was diagnosed preoperatively with Mycetoma.

**Key words:** Mycetoma, Lung Cancer, Aspergilloma.

*How to cite this article*

Soomro NH, Imam S, Zafar A, Shaheen A. Can mycetoma mimic carcinoma of lung? An unusual presentation of aspergilloma: a case report. J Dow Uni Health Sci 2018; 12 (2): 67-70.

## INTRODUCTION

Mycetoma is a tumor-like collection of fungus mixed with mucus and cell debris, inside a cavity, the wall of which shows vascular granulation tissue.<sup>1</sup> On CT-scan chest, a Mycetoma appears as a well-formed cavity with a central soft tissue spherical or ovoid mass bordered by a crescent of air (Monad's sign).<sup>2</sup> The collection may change position with changing position of patient. It is commonly found in the environment. Pulmonary aspergillosis can be sub-divided into five categories: (a) Mycetoma or fungal ball (b) Allergic bronchopulmonary aspergillosis (c) Chronic necrotizing aspergillosis (d) Airway-invasive aspergillosis (e) Angio-invasive aspergillosis.<sup>3</sup> The immuno-compromised are usually the victims of mycetoma. It may also occur more commonly in patients with any structural abnormality of the lung with pre-existing cavities left behind by Tuberculosis (TB), sarcoidosis or bronchiectasis.<sup>4</sup>

---

Department of Thoracic Surgery, Ojha Institute of Chest Disease, Dow University of Health Sciences, Karachi, Pakistan.

### Correspondence:

Dr. Niaz Hussain Soomro

Department of Thoracic Surgery, Ojha Institute of Chest Disease, Dow University of Health Sciences, Karachi, Pakistan

**Email:** niaz.hussain@duhs.edu.pk

## CASE REPORT

A male patient aged 40 years presented to us with complaints of intermittent hemoptysis and shortness of breath along with right side chest pain. He denied weight loss, personal history of smoking or family history of cancer.

On physical examination, he was of average height and built and had stable vitals. On examination of chest, percussion note was dull on the right upper chest with decreased vocal fremitus and air entry in the same region. Patient presented to us had two previous Computed Tomograph (CT) scans and a non-conclusive trucut biopsy.

Bronchoscopy was performed which revealed extensive oropharyngeal candidiasis, but no endobronchial lesions.<sup>1</sup> CT suggested hyperdense mass lesion in right upper lobe (posterior segment) measuring 4 x 5 cm in size.<sup>2</sup> CT scan chest revealed a lobulated branching hyperdense mass seen in right upper lobe measuring 5.8 x 3.8 cm. It also revealed enlarged multiple mediastinal lymphnodes. We advised a fresh CT scan because there had been one year lapse and we wanted to evaluate the current size of the mass and the status of mediastinal lymph nodes. This 3<sup>rd</sup> CT scan revealed large cystic mass extending from right hilum to the apical portion of right upper lobe, and was suspected to be vascular in origin. The case was discussed with the radiologist and CT-angiogram was recommen-

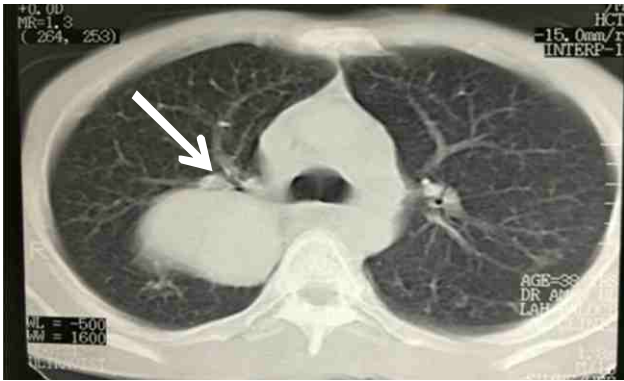


Fig1: 1<sup>st</sup> C.T scan: This Lung window showing hyperdense lesion in right upper lobe (arrow)

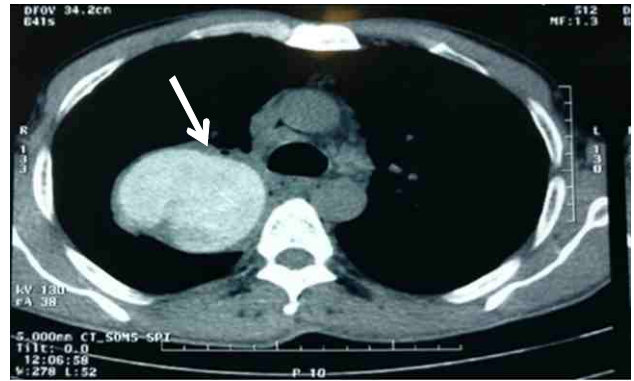


Fig.2 CT-scan showing contrast enhanced lesion in the right upper lobe (arrow)

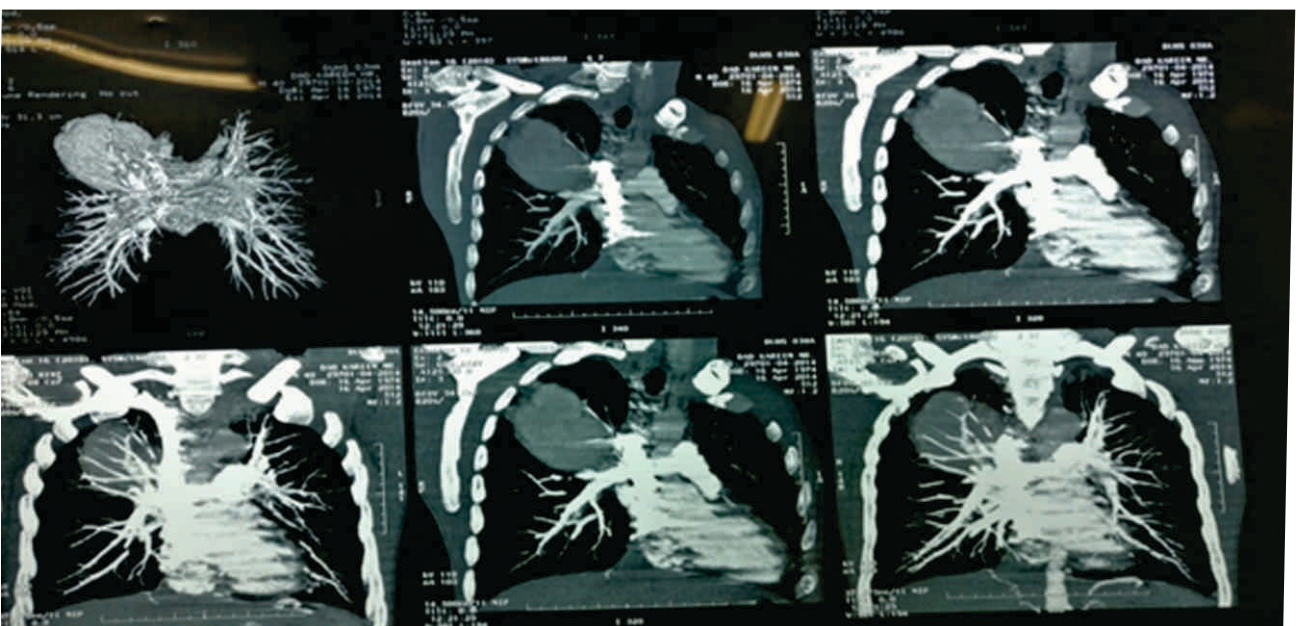


Fig 3 CT Angiogram revealed a large cystic mass showing high attenuations on all phases of imaging. Definitive communication with vessels not found.

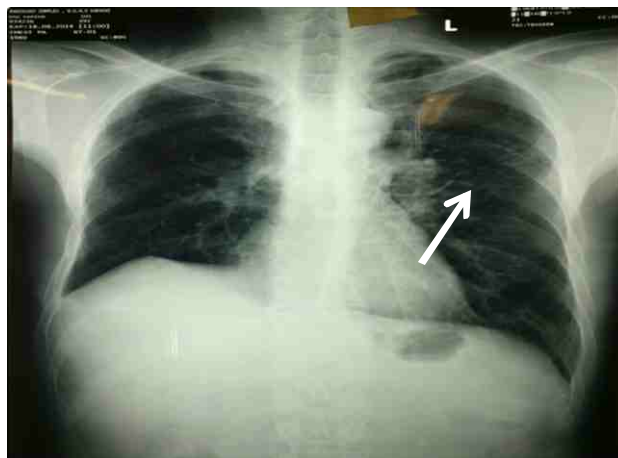


Fig 4: Post-operative chest X ray after thoracotomy and upper lobectomy showing fully expanded both middle and lower lobe (arrow).

ded. Angiogram findings revealed a large cystic mass showing high attenuations on all phases of imaging. Definitive communication with any vessel or bronchi could not be established. After pre-operative work-up, right thoracotomy and right upper lobectomy was performed. Per operatively it was found that upper lobe of lung was densely adherent to anterior chest wall, the adhesions were very vascular and the hard mass of about 10 x 10 cms was palpable in (Rt) the upper lobe. Right upper lobectomy was done. Once the excised lung specimen was opened, a fungal ball was found in the cavity. Fungal smear and fungal culture were sent and final diagnosis of aspergilloma was confirmed. Histology showed a simple aspergilloma with no evidence of malignancy. The postoperative period was smooth and uneventful, and the patient was discharged on the 8<sup>th</sup> post operative day.

## DISCUSSION

Mycetoma is a disease caused by a fungal species *Aspergillus*. Mostly, patients with Mycetoma are asymptomatic. Symptomatic patients experience mild hemoptysis, but some patients present with severe and life-threatening hemoptysis. The mortality rate of hemoptysis related mycetoma is approximately between 2–14%.<sup>5</sup> Our patient presented with intermittent hemoptysis and shortness of breath. Later, he complained of a dry cough.

The pulmonary mycetoma is usually diagnosed on the basis of clinical and radiological features. Others include serological or microbiological evidence of *Aspergillus*. The signs of mycetoma on CT-scan are characterized by the presence of a round or ovoid solid mass with soft-tissue opacity within a lung cavity. Classically, the mass is separated from the cavity wall by an airspace of inconstant size and shape, giving the “air crescent” sign.<sup>6</sup> The aspergilloma usually moves with the change in position. The mass may or may not be calcified. Some times due to the inflammation and vascular granulation tissue formation, the bronchial arteries supplying the wall of the cavity may considerably enlarge and the adjacently located pleura may thicken. On the

other hand, radiologic presentation of lung cancer includes a solitary pulmonary nodule, lung consolidation, collapse, pleural effusion, mediastinal widening and/or a change in the size of the mass as the cancer progresses.<sup>7</sup> In our patient, there was no air crescent sign and the mass increased in size when compared to the previous scan which raised the suspicion of malignancy on radiological ground and presented as well defined solid lesions in the right upper lobe. Park, et al reported that there was a disparity in the CT scan findings of a cavitary lung cancer and a cavitated aspergilloma.<sup>8</sup> He stated that presence or absence of a mural nodule inside the cavity is a key feature which differentiates lung cancer from mycetoma. Fluorodeoxyglucose - Positron emission tomography (FDG-PET scan can help to differentiate lung cancer and mycetoma, but it was not performed due to non-availability in our set up.

Malignant cells uptake FDG which is not possible in aspergilloma, this differentiate malignant lesions from nonmalignant lesions. If patients are symptomatic, medical treatment with antifungals such as oral itraconazole may be attempted because it has a high tissue penetration. Surgical removal of a cavity and fungus ball either by wedge resection or lobectomy is indicated mostly in patients with ongoing hemoptysis, provided their pulmonary function is adequate for proceeding with surgery.<sup>9</sup> In our patient we proceeded with right sided thoracotomy and right upper lobectomy. Postoperatively patient remained stable without hemoptysis and remaining lung fully expanded at six months follow-up.

## CONCLUSION

Sometimes, it is difficult to make an accurate diagnosis of mycetoma by radiographic imaging like CT-scan when “air crescent” sign is absent and the lesion has a solitary mass like appearance which mimics lung cancer. In patient with a low probability of malignancy, other possible diagnosis must be sought. Biopsy or surgical resection is needed for accurate histopathological diagnosis.

## REFERENCES

1. Yasuda M, Nagashima A, Haro A, Saitoh G. Aspergilloma mimicking a lung cancer. *Int J Surg Case Rep* 2013; 4:690-2.
2. Spycher F, Korcher GJ, Gugger M, Geiser T, Ott SR. Pulmonary aspergilloma: A rare differential diagnosis to lung cancer after positive FDG PET scan. *Respir Med Case Rep* 2014; 12:1-3.
3. Kayhan S, Şahin Ü, Bekar Y, Çınarka H, Gümüş A, Bedir R. A case of chronic necrotizing bronchopulmonary aspergillosis presenting with hemoptysis and a pulmonary mass mimicking lung cancer. *Adv Biosci Clin Med* 2014; 2:96-101.
4. Maheshwari V, Varshney M, Alam K, Khan R, Jain A, Gaur K et al. Rare disease: Aspergilloma lung mimicking tuberculosis. *BMJ Case Rep* 2011; 2011.
5. Lee JG, Lee CY, Park IK, Kim DJ, Chang J, Kim SK, Chung KY. Pulmonary aspergilloma: analysis of prognosis in relation to symptoms and treatment. *J thorac Cardiovasc Surg* 2009; 138:820-5.
6. Kim MJ, Lee KS, Kim J, Jung KJ, Lee HG, Kim TS. Crescent sign in invasive pulmonary aspergillosis: frequency and related CT and clinical factors. *J Comput Assist Tomogr* 2001; 25:305-10.
7. Yoon SH, Park CM, Goo JM, Lee HJ. Pulmonary aspergillosis in immunocompetent patients without air-meniscus sign and underlying lung disease: CT findings and histopathologic features. *Acta Radiol* 2011; 52:756-61.
8. Park Y, Kim TS, Yi CA, Cho EY, Kim H, Choi YS. Pulmonary cavitary mass containing a mural nodule: differential diagnosis between intracavitary aspergilloma and cavitating lung cancer on contrast-enhanced computed tomography. *Clin Radiol* 2007; 62:227-32.
9. Chen JC, Chang YL, Luh SP, Lee JM, Lee YC. Surgical treatment for pulmonary aspergilloma: a 28 year experience. *Thorax* 1997; 52:810-3.

