

Diagnostic Accuracy of Magnetic Resonance Cholangio-Pancreatography in Choledocholithiasis

Nasreen Naz and Ummme Aymen

ABSTRACT

Objectives: To estimate the diagnostic accuracy of MRCP in the detection of bile duct calculi in patients with obstructive jaundice using ERCP as gold standard.

Study Design: This is a cross sectional study. The study was conducted at Department of Diagnostic Radiology and Imaging Civil Hospital Karachi, from 01-08-2013 to 31-12-2014.

Materials & Methods: This study comprises 249 cases of clinically observed obstructive jaundice which were referred by hospital consultants or by general practitioner to the Radiology Department for Magnetic Resonance Cholangio-Pancreatography (MRCP). Inclusion criteria were Patients of either gender between 26-70 years of age with obstructive jaundice, raised direct bilirubin levels of 3 mg/dl and above, raised alkaline phosphatase levels and abdominal ultrasound showed suspicion of stone in dilated or non-dilated common bile duct. Previously Diagnosed cases of Choledocholithiasis, patients of chronic liver disease and those for which MRI is contraindicated such as those with surgical clips, braces were excluded from the study. Standard MRI technique carried out for evaluation of bile duct calculi in obstructive jaundice patients. Its features were carefully evaluated in terms of presence and absence of calculus / calculi, dilatation of CBD and pancreatic duct and presence of intrahepatic cholestasis by the consultant radiologist. Data entered and Statistical analyses were carried out by using SPSS version 17. Sensitivity, specificity, diagnostic accuracy positive and negative predictable values were calculated. Mean and frequency distribution for ages and gender was calculated respectively.

Results: Mean age of the patients was 45.54 ± 11.352 years. Gender distribution shows, 42 patients (17%) were male while remaining 207 patients (83%) were female. True positive cases for stones were 145 (58%) and false positive cases were 80 (32%). Positive predictive value was 91.77%, negative predictive value 87.91% with sensitivity 92.95%, specificity 86.02% and Diagnostic accuracy were found to be 90.36%.

Conclusion: It is conclude that Magnetic Resonance Cholangio-Pancreatography (MRCP) is a safe, precise, relatively fast, with no ionizing radiation and non-invasive imaging modality for the assessment of common bile duct stones in patients of obstructive jaundice. The result of this study recommends that MR Imaging showed high Sensitivity and positive predictive values in the detection of bile duct calculi.

Key words: Bile duct calculi, choledocholithiasis, ERCP, MRI, MRCP, obstructive jaundice positive predictive value, negative predictive value.

How to cite this article: Naz N, Aymen U. Diagnostic accuracy of magnetic resonance cholangio-pancreatography in choledocholithiasis. J Dow Uni Health Sci 2016; 10(3): 77-81.

INTRODUCTION

Obstructive Jaundice is a common clinical problem but needs confirmation by imaging¹. The detection of jaundice is based on clinical and laboratory findings but to identify the cause of obstruction it requires different imaging modalities¹. Intrahepatic ducts carries bile from liver to gallbladder and from gallbladder it is drained into duodenum. Mechanical blockage of biliary pathway at any level from liver to gallbladder

and to 2nd part of duodenum can cause obstruction and leads to obstructive jaundice and cholestasis. There are several causes of obstruction at both intrahepatic and extrahepatic level². The most common intraductal cause of obstruction is calculi / calculus, other causes are benign and malignant biliary strictures, neoplasms like cholangiocarcinoma, parasites and primary sclerosing cholangitis. Extraductal causes are compression of biliary channels by periampullary masses, pancreatitis, pseudopancreatic cyst and mucocele¹. The frequency of common bile duct stones is around 10% with high morbidity rates³. The Magnetic Resonance Cholangio-pancreatography (MRCP) has high accuracy rate in the detection of biliary duct calculi in obstructive jaundiced patients. Furthermore it is multiplanar, non-ionizing and non-invasive imaging modality⁴⁻⁸.

Department of Radiology, Civil Hospital and Dow University of Health Sciences, Karachi, Pakistan.

Correspondence: Dr. Nasreen Naz, Department of Radiology, Civil Hospital and Dow University of Health Sciences, Karachi, Pakistan.

Email: nasreenradiologist@gmail.com

For assessment of obstructive jaundice many studies were carried out with different imaging techniques, but previously most of the techniques were invasive and ionizing radiation were used, with the invention of Magnetic Resonance Imaging it became safe, accurate and non-invasive .

The gold standard for examination of the hepatobiliary and pancreatic channel is Endoscopic retrograde cholangio-pancreatography (ERCP)^{9,10}. This is widely used for the diagnostic as well as therapeutic purposes. ERCP is an invasive direct cholangiography technique and thus may contain risks of biliary infection and other complications⁹. Therefore, there is a strong requirement for a less / noninvasive, safe and highly sensitive diagnostic technique for patients with suspected hepatobiliary ductal or pancreatic duct abnormalities¹⁰. Magnetic resonance cholangiopancreatography (MRCP) is an abdominal heavily weighted T2 weighted MR imaging method that requires no contrast administration for visualization of the biliary and pancreatic ducts. It has 88.9% sensitivity and 100% specificity for diagnosing biliary stone disease. Its positive predictive value (PPV), negative predictive value (NPV) and accuracy rates were 100%, 99.2% and 99.2%, respectively¹¹.

Internationally data is available on this topic but available statistics from our part of the World is limited. One study was done locally but there is an issue on sample sizes. All these studies had sample size of less than 100 cases, therefore the present study designed with an appropriate sample size so that true diagnostic accuracy of MRCP could be assessed and decision could be taken for its usage in obstructive jaundice patients in future.

The objective of this study is to determine the diagnostic accuracy of MRCP in revealing the cause of obstructive jaundice which helps in early and prompt treatment and usage of endoscopic retrograde cholangio-pancreatography (ERCP) is limited as a management option

MATERIALS & METHODS

This was a cross sectional study carried out in the department of Radiology, DMC / Civil Hospital Karachi from 01/08/ 2013 to 31 /12/ 2014.. It is estimated as 249 Patients using 95% confidence level with an expected percentage of sensitivity 87.5%, specificity 96.5% and desired precision 12% for sensitivity and 2% for specificity. The sampling technique was non probability consecutive. Inclusion criteria were Patients of either gender between 26 - 70 years of age with obstructive jaundice and level of direct bilirubin 3

mg/dl or above 3mg/dl, raised alkaline phosphatase levels, on abdominal U/S findings of echogenic foci in dilated and non-dilated CBD. Previously diagnosed cases of Choledocholithiasis, patients of chronic liver disease and those patients in which MRI is not indicated such as those with surgical clips and braces were excluded from the study.

Operational Definitions: Presence of stone in common bile duct is known as Choledocholithiasis.

Findings of Choledocholithiasis on MRCP: Presence of hypointense, well circumscribed area in common bile duct on MRCP was labeled as cholidocholithiasis.

Findings of Choledocholithiasis on ERCP: Presence of a filling defect in common bile duct on ERCP were labeled as cholidocholithiasis.

True Positive: Cases with MRCP findings were positive for Choledocholithiasis and confirmed by ERCP.

False Positive: Cases with MRCP findings were positive for Choledocholithiasis but not found to have Choledocholithiasis by ERCP.

False Negative: Cases with MRCP findings were negative for Choledocholithiasis but cholidocholithiasis were positive on ERCP.

True Negative: Cases with MRCP findings were negative for Choledocholithiasis and confirmed by ERCP.

All the patients who fulfilling the above mentioned inclusion criteria were selected, referred from surgical wards and outpatient department for MRCP to the Department of Radiology DMC / Civil Hospital Karachi. Procedure was explained to the patient and written consent was taken, then patient transferred / carried to MRI suite of the Radiology Department. The patient MRCP was conducted on the state of art 1.5 tesla GE machine. Standard protocol for MRCP was followed. The patient was lying in supine position, TORSO PA coils were used in an oblique plane. FOV 32 cm, frequency 256 MHz, NEX1, bandwidth 31.25 and auto frequency of water were used. FRFSE-XL (Fast Recovery Fast Spin Echo-Accelerated) 90 pulse sequence was used and images were obtained in 3D mode. Upper abdomens MRI were included whenever needed. After the MRCP the patient was then sent back to the ward and ERCP was performed within 48 hours of the MRCP by a surgeon or senior consultant (qualified fellow gastroenterologist with at least three years post-degree experience) at Surgical Unit IV of Civil Hospital Karachi. MRCP images were assessed on the viewing console by senior consultant / radiologist to the findings of the ERCP. Its features will be

carefully evaluated in terms of cause of obstruction, intra / extrahepatic cholestasis, dilatation of CBD and pancreatic duct by the consultant radiologist having at least five years of experience in both MRCP and ultrasound.

Data so collected were entered on SPSS version 17.0. Mean and standard deviation were calculated for age. Frequency and percentages were calculated for qualitative variable like gender and presence of stone on MRCP and ERCP. Sensitivity, specificity, PPV and NPV and diagnostic accuracy were calculated by taking ERCP as gold standard. Effect modifiers were reported for age and gender to see the effect of these on outcomes. Post stratification chi-square tests were applied taken $p = 0.05$ as significant.

All procedures followed were in accordance with the ethical standards of the responsible committee on human experimentation (institutional and national) and with the Helsinki Declaration of 1975, as revised in 2008. Informed consent was obtained from all patients for being included in the study.

RESULTS

In this study two hundred and forty-nine (249) patients were enrolled to assess the diagnostic accuracy of the Magnetic Resonance Cholangio-pancreatography (MRCP) for detection of bile duct calculi in patients of obstructive jaundice using ERCP as gold standard. Mean age of the patient was 44.5 years with the standard deviation of ± 11.3 years. Similarly, Out of total 249 patients, 42 (17%) patients male while 207 (83%) patients were female and female to male ratio were 1:4.9.

True positive cases for stone were 156 and true negative cases 80. In non-calculus cases stricture were the cause of obstruction both benign and malignant. Overall diagnostic accuracy of MRI is shown in Table 1 & 2.

Table 1: Diagnostic accuracy of MRCP in detection of bile duct calculi keeping ERCP as gold standard (n=249)

RESULTS OF MRCP	ERCP	
	Positive	Negative
MRCP (Positive)	145	13
MRCP (Negative)	11	80
Total	156	93

Table 2: Diagnostic accuracy of MRCP in detection of bile duct calculi keeping ERCP as gold standard (n=249)

	%
Sensitivity	92.95
Specificity	86.02
PPV	91.77
NPV	87.91
Diagnostic Accuracy	90.36

Sensitivity and Specificity was found to be 92.95 and 86.02% respectively. Positive predictive value was found to 91.77% and negative predictive value was 87.91%, and over all accuracy found 90.36%. Image of MRCP showing calculus at distal CBD as shown in Figure 1.

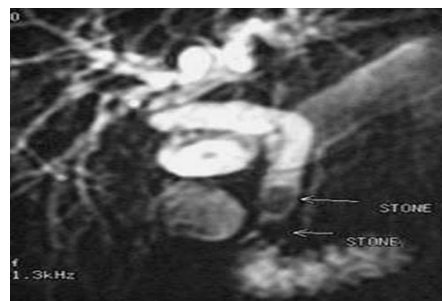


Figure 1. MRCP: Multiple stones in distal CBD with proximal Cholestasis

DISCUSSION

The purpose of this research study was to determine the diagnostic accuracy of Magnetic Resonance Cholangio - Pancreatography (MRCP) in patients of obstructive jaundice to find out whether stone is a cause of obstruction, by keeping ERCP as gold standard. We evaluated diagnostic accuracy on the basis of sensitivity, specificity, positive predictive and negative predictive values. If these values were suitable for MRCP, then the ERCP could be proposed as the examination of choice for bile duct abnormalities and could be reserved for therapeutic intervention. There are different hepatobiliary imaging methods available like US, CT, MRI, MRCP, ERCP and PTC.

Ultrasound is the initial imaging investigation in patients suffering from obstructive jaundice. Now days the pattern of diagnostic approach in hepatobiliary system has been completely revolutionized. However despite the development of high tech imaging modalities, ultrasound is still considered the initial choice in the diagnosis of choledocholithiasis as it is readily available. The sensitivity of ultrasound in choledocholithiasis varies between 20– 80%¹². On the other hand distal CBD stones are usually missed on ultrasound due to overlying duodenal gases of the patient¹². Also the diagnostic value of ultrasound in common bile duct is inconstant and limited, as it depends on operator’s experience and patient’s preparations. Hence these complications have indirectly led to the growing popularity of MRCP.

MRCP is a noninvasive and non-ionizing imaging modality whereas ERCP is ionizing and invasive, associated with 1-7% of morbidity^{13,14}. With the continuous progression and improvement of high resolution equipment, scanning procedure and

interpretive skills, there are high levels of diagnostic achievements to determine the specific cause of biliary tract or common bile duct obstruction^{15,16}. The radiological diagnostic accuracy when combined with clinical data is approaching 98 percent¹⁷. Liang CA, Mao HE¹⁸ reported that sensitivity of MRCP is 85% in the diagnosis of common bile duct stones which are the most common cause of hepatic obstruction¹⁹. The sensitivity of MRCP was raised to 88% in the other two studies^{20,21}. This systematic review shows evidence that MRCP stands up well to comparisons with diagnostic ERCP, for the diagnosis of many hepatobiliary channel abnormalities. It appears that ERCP is an adequate reference standard for choledocholithiasis with sensitivities and specificities above 89%, however the results for malignancy were much less reliable. The evidence on patient satisfaction shows that patients prefer MRCP over diagnostic ERCP. The results of our review are similar to those found by Romagnuolo et al¹⁴ who in their meta-analysis showed high levels of sensitivity and specificity for demonstrating the level and presence of biliary obstruction.

In our study the mean age of the patients was 44.54±11.352years. According to the study of Khurram SE, Qasim AI¹⁵, the mean age of the patients was 48.54±9.86years, which is close to the results of our study. Furthermore in the present study there were 83% female patients and 17% male patients. This gender distribution is comparable with the study of Mehmet BN, HuseyinTK, et al¹⁶ where there were 19% male and 81% female patients.

In this study, the positive predictive value of MRCP was 91.77%, diagnostic accuracy was 90.36% with sensitivity 92.95% and specificity 86.02%. In another study conducted by Hina GL, Sameer WD²², the reported sensitivity was 93.5% and specificity 85.6% of MRCP with diagnostic accuracy of 88.78%, which is much more alike & comparable with our conducted research study. On the light of above discussion, it is concluded that MRCP proved high diagnostic accuracy in the detection of bile duct calculi in patients with obstructive jaundice taking ERCP as gold standard. Our study has a few limitations; it is a single center study and it was conducted with an urban environment therefore the results might not be generalizable to larger populations.

CONCLUSION

It is concluded from this study that MRCP is a comparable diagnostic investigation in contrast to ERCP for diagnosing bile duct calculi. MRCP is non-ionizing, easily available and a non-invasive imaging modality. MRCP is much better in determining the

extent of the disease and its complications. It is also concluded from the results of this study that MRCP proved high diagnostic accuracy as well as positive predictive value in the detection of choledocholithiasis and has the potential to replace diagnostic ERCP.

REFERENCES

1. Khan TQ, Ahmed S, Amin Y et al. It's not always a stone- filling defect in the bile ducts. *Pak J Radiol* 2003; 15:30.
2. Khurram M, Durrani AA, Hasan Z, Butt AA, Ashfaq S. Endoscopic retrograde cholangiopancreatographic evaluation of patients with obstructive jaundice. *J Coll Physicians Surg Pak* 2003; 13:325-8.
3. Petelin JB. Laparoscopic common bile duct exploration: lessons learned from > 12 years experience. *Surg Endosc* 2003, 17:1705-15.
4. Kaltenthaler EC, Walters SJ, Chilott J, Blakerborough A, Vergel YB, Thomas S. MRCP compared to diagnostic ERCP for diagnosis when biliary obstruction is suspected: a systematic review. *BMC Med Imaging* 2006; 6:9.
5. Di Cesare E, Puglielli E, Michelini O, Pistoia MA, Lombardi L, Rossi M, et al. Malignant obstructive jaundice: comparison of MRCP and ERCP in evaluation of distal lesions. *Radiol Med* 2003; 105:445-53.
6. Hekimoglu K, Ustundag Y, Dusak A, Erdem Z, Karademir B, Aydemi S, et al. MRCP vs ERCP in the evaluation of biliary pathologies: review of current literature. *J Dig Dis* 2008; 9:162-9.
7. Iannicelli E, Sessa A, Argnani L, Galluzzo A, David V. [Role of MR Cholangiopancreatography in the evaluation of biliary disease]. *ClinTer* 2006; 157:425-9.
8. Park DH, Kim MH, Lee SS, Lee SK, Kim KP, Han JM, et al. Accuracy of magnetic resonance cholangiopancreatography for locating hepatolithiasis and detecting accompanying biliary strictures. *Endoscopy* 2004; 36:987-92.
9. Tsukada K, Takada T, Miyazaki M, Miyakawa S, Nagino M, Kondo S, et al. Diagnosis of biliary tract and ampullary carcinomas. *J Hepatobiliary Pancreat Surg* 2008; 15:31-40.
10. Ralls PW, Jeffrey RB, Kane Ra, Robbin M. Ultrasonography. *Gasroenterol Clin North Am* 2002; 31:801-25.
11. Murfitt J. The pancreas. In Sutton D. *Textbook of radiology and imaging*. 7th ed. London: Churchill Livingstone 2003; 787-823.
12. Munir K, Bari V, Yaqoob J, Khan DBA, Usman MU. Role of magnetic resonance cholangio-pancreatography (MRCP) in obstructive jaundice. *J Pak Med Assoc* 2004; 54:128-32.

13. Lo SK, Chen J. The role of ERCP in choledocholithiasis. *Radiology* 2002; 224:410-16.
14. Romagnuolo J, Bardou M, Rahme E, Joseph L, Reinhold C, Barkun AN: Magnetic Resonance Cholangiopancreatography: A meta-Analysis of Test Performance in Suspected Biliary Disease. *Annals Internal Med* 2003, 139:547-57.
15. Khurram SE, Qasim AI, Shirin MA. Evaluation of the Aetiological Spectrum of Obstructive Jaundice. *J Ayub Med Coll Abbottabad* 2008; 20:62-6.
16. Mehmet BN, Huseyin TK, Mehmet BI. Diagnostic Value of Dynamic Contrast-Enhanced Magnetic Resonance Imaging in the Evaluation of the Biliary Obstruction. *Scientific World J* 2012; 1-9.
17. Fulcher AS, Turner MA. MR cholangiopancreatography. *RCNA* 2002; 40:1363-76.
18. Liang CA, Mao HE. Diagnostic Performance of Magnetic Resonance Cholangiopancreatography in Malignant Obstructive Jaundice. *Cell Biochem Biophys* 2011; 61:383-8.
19. Koray HU, Yucel UG. MRCP vs ERCP in the evaluation of biliary pathologies: Review of current literature. *J Digestive Dis* 2008; 9:162-9.
20. Nyree GN, Geoff CS. Magnetic resonance cholangiopancreatography: the ABC of MRCP. *Insights Imaging*. 2012; 3:11-21.
21. Macciono F, Martinelli M, Al Ansari N, Kagarmanova A, De Marco V, Zippi M, et al. Magnetic resonance cholangiography; past, present and future; a review. *Eu Rev Med Pharmacol Sci* 2010; 14:721-5.
22. Hina GL, Sameer WD. Utility of Magnetic Resonance Cholangio-pancreatography in the evaluation of biliary tract obstruction. *J Med Sci* 2010; 18:97-100.

